Infestations 84

Craig N. Burkhart, Craig G. Burkhart and Dean S. Morrell

Chapter Contents

Scabies 1519
Head Lice 1523
Crab Lice 1526
Body Lice 1527
Tungiasis 1528
Cutaneous Myiasis 1529

SCABIES

Synonyms: ■ Itch mite infestation ■ "Seven-year itch"

Key features

- Human scabies is a pruritic condition caused by infestation with the host-specific mite *Sarcoptes scabiei* var. *hominis*, which lives its entire life within the epidermis
- Although the scabies mite is not a known vector for any systemic disease, secondary bacterial infections with *Streptococcus pyogenes* or *Staphylococcus aureus* may develop
- Transmission typically occurs via direct close contact with an infested person; fomite transmission is also possible, especially with the crusted variant
- Permethrin 5% cream is generally the first-line treatment for classic scabies

Introduction

The scabies mite continues to plague all countries of the world[1]. An estimated 150–200 million individuals are affected globally, with an overall worldwide prevalence of ~2.5%[2,3]. In 2017, the World Health Organization (WHO) designated scabies as a neglected tropical disease to highlight the need for global control strategies. Pruritus associated with this infestation is usually severe, especially at night, and treatment typically requires prescription scabicidal therapy.

History

Scabies has been a common companion of the human species for over 2500 years[1].

Epidemiology

Scabies is a worldwide problem and all ages, races, and socioeconomic groups are susceptible. Environmental factors that promote its spread include overcrowding, institutional settings, delayed treatment, and lack of public awareness of the condition. There is considerable variation in the prevalence of scabies, with rates in low-income countries ranging from 4% to 70%[1–3]. Higher incidences occur in tropical regions, and outbreaks may occur in the setting of natural disasters, wars, economic depression, and refugee displacement[1,4]. Scabies can be transmitted directly by close personal contact, sexual or otherwise, or indirectly via fomites. Prevalence is higher in children and people who are sexually active, and spread of the infestation among family members and other close contacts is common[4]. The scabies mite is not a known vector for systemic disease.

Crusted scabies (formerly called Norwegian scabies) is found in individuals with compromised immune systems, such as the elderly, people infected with HIV or human T cell lymphotropic virus type 1 (HTLV-1), and solid organ transplant recipients; it can also occur in those with decreased sensory functions and/or ability to scratch (e.g. patients with leprosy or paraplegia). These patients may experience minimal pruritus despite their infestation with a large number of mites and are highly contagious[4].

Pathogenesis

The species-specific, eight-legged mite *Sarcoptes scabiei* var. *hominis* causes human scabies (Fig. 84.1). The *Sarcoptes* mites that cause infestations in animals (e.g. *S. scabiei* var. *canis* in dogs) are not a source of human infestation, but they can produce bite reactions (see Ch. 85). The scabies mite is 0.35 × 0.3 mm in size and too small to be seen by the naked eye. The entire 30-day life cycle of these mites is completed within the epidermis (Fig. 84.2). Each day a female mite lays 2–3 eggs, which require approximately 10 days to mature. The number of mites living on an infested host can vary greatly, although there are usually fewer than a hundred and often no more than 10–15. However, patients with crusted scabies may have thousands of mites on their skin surface, and live mites can be recovered in debris from sheets, the floor, curtains, and chairs in the environment of affected individuals[5]. Scabies mites usually live 3 days or fewer off a human host, but those from patients with crusted scabies may live up to 7 days by feeding on sloughed skin.

The incubation period before symptoms develop can range from days to months. In first-time infestations, it usually takes 2–6 weeks before the host's immune system becomes sensitized to the mite or its by-products, resulting in pruritus and cutaneous lesions. In contrast, a subsequent infestation often becomes symptomatic within 24–48 hours. Asymptomatic scabies-infested individuals are not uncommon, and they can be considered "carriers"[5].

Clinical Features

The epidemiologic history (e.g. pruritus in household members or other close personal contacts), the distribution and types of lesions, and pruritus form the basis of the clinical diagnosis. The intense pruritus is classically accentuated at night and by a hot bath or shower. Pruritus may be present before any overt physical signs appear and is thought to be mediated by nonhistaminergic mechanisms[6]. Cutaneous lesions are symmetrical, typically involving the interdigital web spaces of the hands, flexural aspect of the wrists, axillae, posterior auricular area, waist (including the umbilicus), ankles, feet, and buttocks. In men, penile and scrotal lesions are common, while in women, the areolae, nipples, and vulvar area are often affected. In infants, the elderly and immunocompromised hosts, all skin surfaces are susceptible, including the scalp and face[1,5].

Typically, small erythematous papules are present in association with a variable degree of excoriation (Fig. 84.3A–C). Vesicles, indurated nodules, and eczematous dermatitis are also common (Fig. 84.3B–F). The pathognomonic sign is the burrow, representing the tunnel that a female mite excavates while laying eggs. Clinically, the burrow is wavy, thread-like, grayish-white, and 1–10 mm in length (Fig. 84.3G). Many patients, however, do not have obvious burrows on inspection, especially in warm climates.

Acral vesiculopustules can represent a clue to the diagnosis of scabies in infants (see Fig. 84.3D). Crusted scabies often manifests with marked hyperkeratosis that favors acral sites including subungual areas,

Downloaded for Anonymous User (n/a) at Egyptian Knowledge Bank from ClinicalKey.com by Elsevier on March 10, 2024. For personal use only. No other uses without permission. Copyright ©2024. Elsevier Inc. All rights reserved.

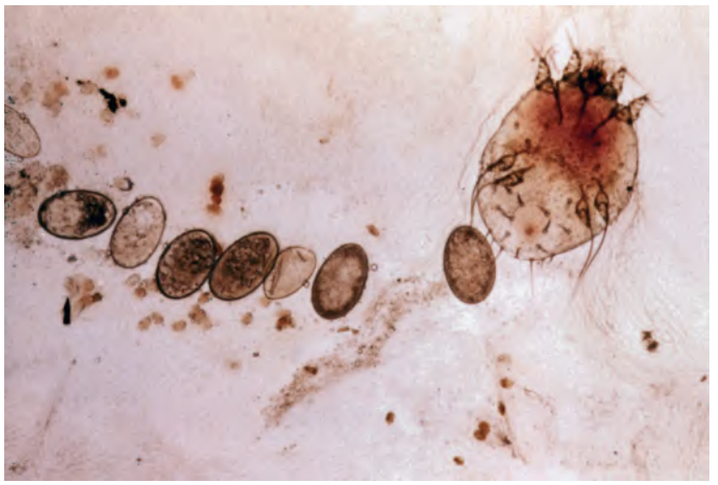

Fig. 84.1 Female scabies mite with eggs and scybala in skin scrapings. Note the mite's flattened, oval body and eight legs.

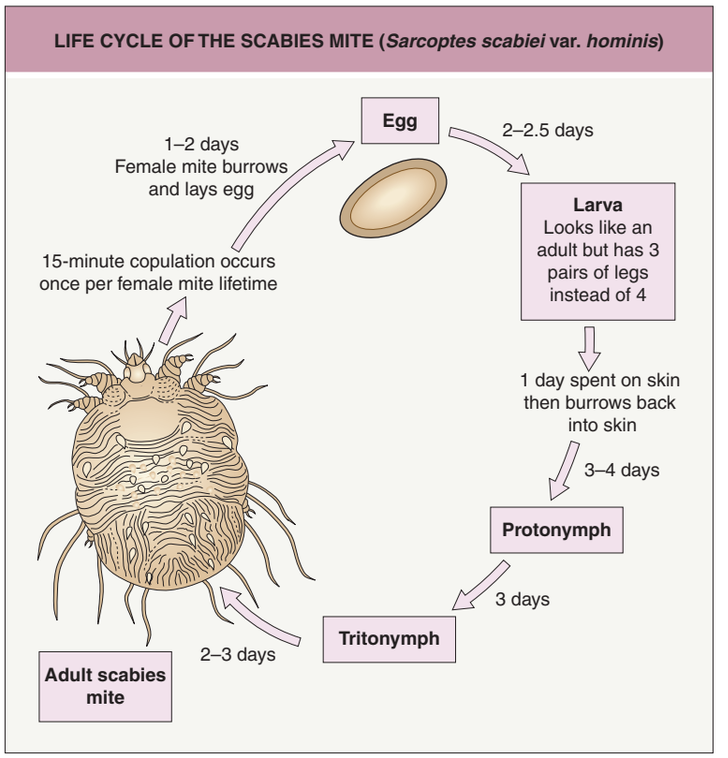

Fig. 84.2 Life cycle of the scabies mite (*Sarcoptes scabiei* var. *hominis*).

Fig. 84.3 Scabies. A–C Erythematous papules and oozing dermatitic plaques in infants with scabies. **D** Vesiculopustules on an infant's foot. Similar findings are seen in acropustulosis of infancy, which can occur following successful scabies treatment. **E** Penile involvement with erythematous papules and nodules. **F** Nodular scabies in an infant. **G** Classic scabetic burrows. Burrows are of high yield for visualizing mites via dermoscopy and isolating mites via skin scraping. *A–D, Courtesy Julie V. Schaffer, MD; F, Courtesy Kalman Watsky, MD.*

Downloaded for Anonymous User (n/a) at Egyptian Knowledge Bank from ClinicalKey.com by Elsevier on March 10, 2024. For personal use only. No other uses without permission. Copyright ©2024. Elsevier Inc. All rights reserved.

Fig. 84.4 Crusted scabies. Scabies incognito presenting as an asymptomatic hyperkeratotic "rash" on the hand in a patient with impaired sensory function (**A**) and on the abdomen of a hospitalized man (**B**). *A, Courtesy Joyce Rico, MD; B, Courtesy Kalman Watsky, MD.*

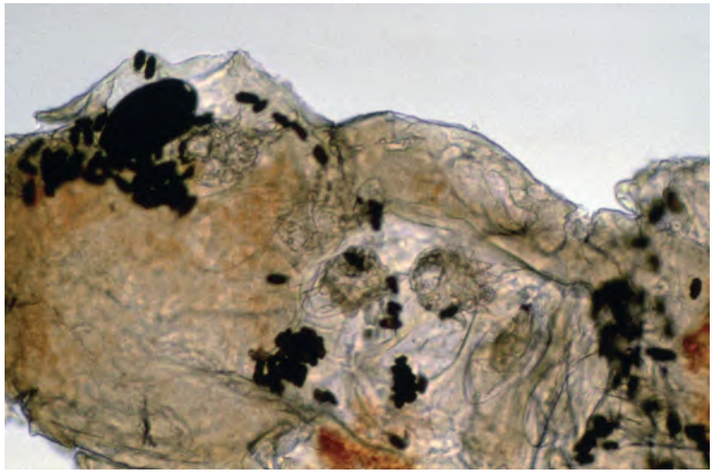

Fig. 84.5 Microscopy of a skin scraping from a patient with scabies. Four mites, eggs, and scybala are present. The mites blend in with the background scale, making them difficult to see.

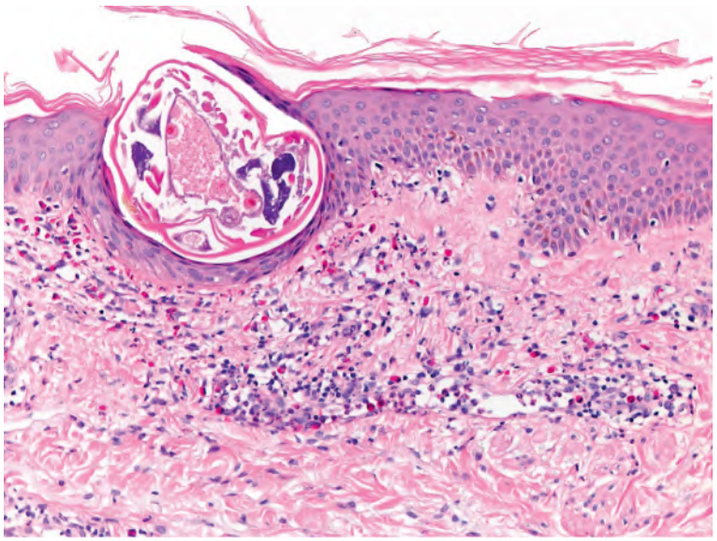

Fig. 84.6 Scabies – histologic features. A mite is evident in the stratum corneum and an eosinophil-rich dermal infiltrate is present. *Courtesy Lorenzo Cerroni, MD.*

but involvement may be widespread (Fig. 84.4). Areas of affected skin have been referred to as pachyderma.

Secondary bacterial infections with *Staphylococcus aureus* or *Streptococcus pyogenes* sometimes complicate scabies. In resource-poor countries with endemic scabies, post-streptococcal glomerulonephritis is a significant issue. Peripheral eosinophilia can be the primary sign of scabies in patients with disorders of keratinization.

Confirmation of the diagnosis can be achieved by light microscopic examination of mineral oil preparations of skin scrapings (from infested areas) for adult mites, eggs, and/or fecal pellets (scybala; Fig. 84.5). A scalpel or curette may be used to obtain the skin sample[7]. Microscopic examination of transparent adhesive tape following its application to infested areas of skin represents another diagnostic technique. Dermoscopy and confocal microscopy can prove useful for direct *in vivo* visualization of mites and eggs (see Fig. 84.5). Recent consensus criteria for a *confirmed* scabies diagnosis require visualization of mites, eggs, or feces either by light microscopy of skin samples or on an individual by a high-powered imaging device or dermoscopy[8]. A skin biopsy may confirm the clinical diagnosis, but only if the specimen obtained happens to contain the mite or its eggs. Often, however, the diagnosis is a clinical one, resting on history and physical findings (e.g. burrows, genital lesions)[8] as well as response to treatment. The diagnostic potential of PCR-based analysis of skin scrapings or swabs and serologic testing to detect IgE specific for a recombinant *S. scabiei* antigen are under investigation[9,10].

Pathology

A patchy to diffuse infiltrate with prominent eosinophils as well as lymphocytes and histiocytes is noted in the reticular dermis. A transected scabies mite may occasionally be seen within the epidermis (Fig. 84.6). Pink "pigtail"-like structures attached to the stratum corneum, which represent fragments of the adult mite exoskeleton, can serve as a clue to the diagnosis of scabies when entire mites, scybala, and eggs are not identified[11].

Differential Diagnosis

Unless burrows or (via dermoscopy) mites and eggs are noted clinically, a wide variety of pruritic skin diseases should be considered in the differential diagnosis. These include atopic, allergic contact, autosensitization ("id" reaction), and nummular dermatitis as well as arthropod bites, pyoderma, dermatitis herpetiformis, and bullous pemphigoid. Occasionally, scabies can mimic Langerhans cell histiocytosis clinically and histologically, as a dense infiltrate of Langerhans cells may be present. The clinical and histologic features of infantile scabies may also resemble findings in the inflammatory stage of incontinentia pigmenti. Acropustulosis of infancy can both mimic scabies and follow scabies as a hypersensitivity phenomenon.

Downloaded for Anonymous User (n/a) at Egyptian Knowledge Bank from ClinicalKey.com by Elsevier on March 10, 2024. For personal use only. No other uses without permission. Copyright ©2024. Elsevier Inc. All rights reserved.

TOPICAL AND ORAL TREATMENTS FOR SCABIES					
Therapy	**Administration**	**Concerns**	**Efficacy & resistance**	**Use in infants**	**Use in pregnancy**
Permethrin cream (5%)	Topically overnight (8–12 hours) on days 1 and 8*	Allergic contact dermatitis in individuals with sensitivity to formaldehyde	Excellent, but some signs of tolerance developing	FDA approved for infants ≥2 months of age	Considered safe
Spinosad suspension (0.9%)	Topically for ≥6 hours on day 1	Skin irritation, dry skin	Good	FDA approved for children ≥4 years of age	Considered safe
Lindane lotion or cream (1%)	Topically overnight on days 1 and 8	Potential CNS toxicity, especially in individuals weighing <110 pounds (50 kg), the elderly and those with crusted scabies, other skin conditions or a history of seizures	Poor, resistance very common	Not recommended for infants, children or breastfeeding mothers; contraindicated in premature infants	Not recommended
Crotamiton lotion or cream (10%)	Topically overnight for 2–5 consecutive days	Irritant contact dermatitis, especially in areas of denuded skin	Very poor; has antipruritic properties and may be used for postscabetic pruritus	Considered safe	Not established
Sulfur ointment (5%–10%)	Topically overnight for 3 successive days	Toxicity studies not performed	Good	Considered safe	Considered safe
Benzyl benzoate lotion or emulsion (10%–25%)	Topically (left on for 24 hours) on days 1 and 8	Irritant contact dermatitis	Good	Not well established	Not established
Ivermectin	Oral dose of 200 mcg/kg on day 1 and repeated on day 8 or 14*,† (available as 3 mg tablets)	Potential risk of CNS toxicity in infants and young children	Excellent	Not well-established, although recent studies suggest safety in children (age ≥1–2 months) weighing <33 pounds (15 kg)	Generally not recommended for scabies in pregnant women
	0.5%–1% lotion/cream topically overnight on days 1 ± 8	Potential skin and eye irritation	Not established	Not established	

*For crusted scabies, the CDC recommends: (1) topical permethrin 5% every 2–3 days for 1 to 2 weeks; (2) oral ivermectin (200 mcg/kg/dose) administered as three doses (days 1, 2 and 8), five doses (days 1, 2, 8, 9, and 15), or seven doses (days 1, 2, 8, 9, 15, 22, and 29), depending upon the severity of the infection; and (3) application of a topical keratolytic (e.g. salicylic or lactic acid) in areas of hyperkeratosis (www.cdc.gov).
†Administration of second dose at 1 week is recommended by the CDC (www.cdc.gov).

Table 84.1 Topical and oral treatments for scabies. Topical therapies for scabies require careful instructions to ensure correct application by patients.

Treatment

Two treatments 1 week apart with an antiscabetic medication are typically recommended, with permethrin 5% cream a standard first-line therapy (Table 84.1)[4,12]. Topical preparations are applied to the entire body surface, from head to toe, in infants and the elderly. In other age groups, the face and scalp can be excluded from treatment. Special attention should be paid to the interdigital spaces, intergluteal cleft, umbilicus, and subungual areas. To reduce the potential for reinfestation by fomite transmission, at the time of each treatment, clothing, linens, and towels used within the previous week can be either washed in hot water and dried on high heat or stored in a bag for 7–10 days[13]. The relatively common occurrence of asymptomatic mite carriers in households necessitates that all family members and other close contacts be treated simultaneously, even if they have not developed any pruritus or clinical signs. Pets cannot harbor human mites and do not have to be treated. Secondary bacterial infections should be treated with appropriate antibiotics.

Following successful treatment, pruritus and skin lesions can persist for 2–4 weeks or longer, especially for acral vesiculopustules in infants and nodules. This is referred to as "postscabetic" pruritus or dermatitis. Patients should be informed that such reactions do not imply treatment failure, but rather represent the body's response to dead mites that are eventually sloughed off (within 2 weeks) along with normal epidermal exfoliation. Many patients, however, experience relief from pruritus within 3 days. The second treatment is performed in order to reduce the potential for reinfestation from fomites as well as to ensure killing of any nymphs that may have survived within the semi-protective environment of the egg and subsequently hatched (see Fig. 84.2).

Permethrin

Permethrin is a synthetic pyrethroid formulated in a 5% cream that is currently the standard topical scabicide[4,12,14a]. Like other pyrethroids, it inhibits sodium transport in arthropod neurons, thereby causing paralysis. Adverse reactions are rare and are usually related to brief stinging on application. Prolonged *in vitro* survival of *S. scabiei* var. *hominis* following permethrin exposure has been noted, but clinical resistance has not been documented.

Spinosad

In 2021, 0.9% spinosad suspension was FDA-approved for the treatment of scabies in patients ≥4 years of age. In a randomized clinical study (n=206), a single application of 0.9% spinosad suspension to the entire body (neck to toes; left on for ≥6 hours) led to a complete cure on day 28 in 78% of patients with scabies, compared to 40% for placebo ($p<0.001$)[14b].

Lindane

Lindane (gamma-hexachlorocyclohexane), an organochlorine agent, is marketed in a 1% lotion and cream. CNS side effects may occur from increased percutaneous absorption through damaged skin, misuse, overuse, or accidental ingestion. Because of the potential for CNS toxicity, lindane is contraindicated in premature infants, individuals with crusted scabies or pre-existing skin conditions (e.g. extensive atopic dermatitis) that may increase its systemic absorption, as well as patients with an uncontrolled seizure disorder. Potential toxicity, relatively poor efficacy, widespread resistance, and issues related to environmental contamination make lindane an inferior treatment choice compared to permethrin or oral ivermectin. In 2003, the US Food and Drug Administration (FDA) issued a "black box" warning for lindane products, stating that they should be used with caution in infants, children, other individuals who weigh <110 pounds (50 kg), and the elderly due to an increased risk of neurotoxicity[4].

Crotamiton

An alternative scabicide is crotamiton, which is formulated in a 10% lotion and cream. Although it has an antipruritic effect, crotamiton

Downloaded for Anonymous User (n/a) at Egyptian Knowledge Bank from ClinicalKey.com by Elsevier on March 10, 2024. For personal use only. No other uses without permission. Copyright ©2024. Elsevier Inc. All rights reserved.

can cause irritation of denuded skin and is less effective than the other prescription options[15].

Sulfur ointment

Another alternative therapy for scabies is three consecutive overnight applications of 5%–10% sulfur in a petrolatum base. A pharmacist must compound the medication, and toxicity studies have not been performed. Sulfur is messy, malodorous, and irritating to the skin and can stain clothing. However, its efficacy has been reported to be as high as 60%–96% with three consecutive 24-hour applications[16a].

Benzyl benzoate

Benzyl benzoate is an ester of benzoic acid and benzyl alcohol that is neurotoxic to mites. It is available over-the-counter (OTC) in a 10%–25% lotion or emulsion (not directly sold in US pharmacies; lower concentrations used in children) that is left on for 24 hours. Regimens include: 2-3 applications over a 24-hour period; applications on 3 consecutive days; and applications on day 1 and day 8. Cure rates of ~90% have been reported, and the main side effect is skin irritation[16b].

Ivermectin

Ivermectin is a macrocyclic lactone produced by *Streptomyces avermitilis*. Although not FDA-approved for scabies, ivermectin represents an effective treatment for this and other ectoparasitic infestations[1,17]. By blocking transmission across nerve synapses that utilize glutamate or γ-aminobutyric acid (GABA), ivermectin causes paralysis of peripheral motor function in insects and acarines[1,17]. Although GABA and glutamate are neurotransmitters within the human cerebral cortex, after early infancy, the blood–brain barrier prevents CNS penetration of the drug. However, neurotoxicity can occur in rare individuals with biallelic nonsense mutations in the *ABCB1* (ATP-binding cassette subfamily B member 1) gene encoding the P-glycoprotein that functions in the blood–brain barrier[18]. Ivermectin is not recommended for pregnant women or breastfeeding mothers because of the lack of safety data in these groups[1]. Oral ivermectin treatment for scabies in infants and children weighing <33 pounds (15 kg) was well-tolerated in a recent large series,[19] although traditionally not recommended in this group.

In clinical studies, oral ivermectin has proven to be extremely safe. Over 18 million people >5 years of age have been treated annually with ivermectin in the WHO Onchocerciasis Eradication Program. An increased death rate in elderly patients who received ivermectin in a single retrospective study[20] was determined to be causally unrelated to the medication by the WHO, medical examiners, and the scientific community. A related medication with a longer half-life, moxidectin, was recently FDA-approved for onchocerciasis and is under investigation as a potential scabies treatment[4].

For treatment of scabies, an oral ivermectin dose of 200 mcg/kg is usually administered twice, 1–2 weeks apart[1,17]. Although there is only one report to date of clinical resistance to this agent by the scabies mite, increased *in vitro* survival times of mites exposed to ivermectin have been described in communities with a high prevalence of scabies[21]. In areas with endemic disease, mass administration of oral ivermectin or topical permethrin (± coadministration of azithromycin) can help to control scabies and reduce the prevalence of impetigo[22].

Topical ivermectin in a 1% concentration (FDA-approved for the treatment of rosacea) also appears to be effective for scabies, but further study is warranted before recommending its routine use for this indication[23]. In patients with subungual disease, addition of a topical scabicide is recommended because a systemic medication will not penetrate into thickened keratotic debris. A combination of oral ivermectin and topical permethrin is often required to treat patients with crusted scabies (see Table 84.1), and use of a topical keratolytic agent (e.g. salicylic or lactic acid) can help to decrease the associated hyperkeratosis.

HEAD LICE

Synonyms: ▪ Pediculosis capitis ▪ "Cooties"

Key features

- This worldwide infestation is caused by bloodsucking, wingless, six-legged insects that live only on the hairs of the scalp
- Diagnosis is usually confirmed by the presence of 0.8 mm eggs ("nits") firmly attached to scalp hairs
- Head lice are spread by head-to-head contact as well as by fomite transmission
- Resistance to traditional over-the-counter preparations (pyrethrins, permethrin) is growing
- Newer treatments, including topical ivermectin, are now available

Introduction

Lice are bloodsucking, wingless insects belonging to the suborder Anoplura. Twelve million cases per year occur in the US alone, and resistance to traditional treatments is increasing. Prescription products (e.g. topical malathion, topical or oral ivermectin) are often needed to treat resistant cases, requiring greater physician involvement.

History

Head lice have infested mankind for thousands of years. Nits have been found on the hair of Egyptian and Peruvian mummies[1].

Epidemiology

Head lice are found worldwide with no strict limitations based upon age, sex, race, or socioeconomic class. Children 3–11 years of age have the highest incidence. The worldwide prevalence in school-aged children was estimated to be 19% in a recent meta-analysis, with prevalences as high as 60% in some countries[1,24]. Infestation with head lice is more frequent in girls, probably due to their tendency to have longer hair as well as to exchange brushes, barrettes, and other hair accessories. Head lice are distinctly uncommon in African-Americans, as head lice in the US are unable to properly position themselves to lay eggs on coarse curly hair[20].

Pathogenesis

The head louse, *Pediculus capitis*, is a highly host-specific insect approximately the size of a sesame seed (2–3 mm; Fig. 84.7). These obligate human parasites feed on the blood of the host approximately every 4–6 hours. The female louse lives for 30 days, during which time she lays between 5 and 10 eggs a day on hair shafts (Fig. 84.8). The

Fig. 84.7 Head louse family. From left to right: female, male, and nymph. *With permission from Taplin D, Meinking TL. Infestations. In: Schachner LA, Hansen RC (eds). Pediatric Dermatology, 4th edn. Edinburgh: Mosby, 2011:1141–80.*

Downloaded for Anonymous User (n/a) at Egyptian Knowledge Bank from ClinicalKey.com by Elsevier on March 10, 2024. For personal use only. No other uses without permission. Copyright ©2024. Elsevier Inc. All rights reserved.

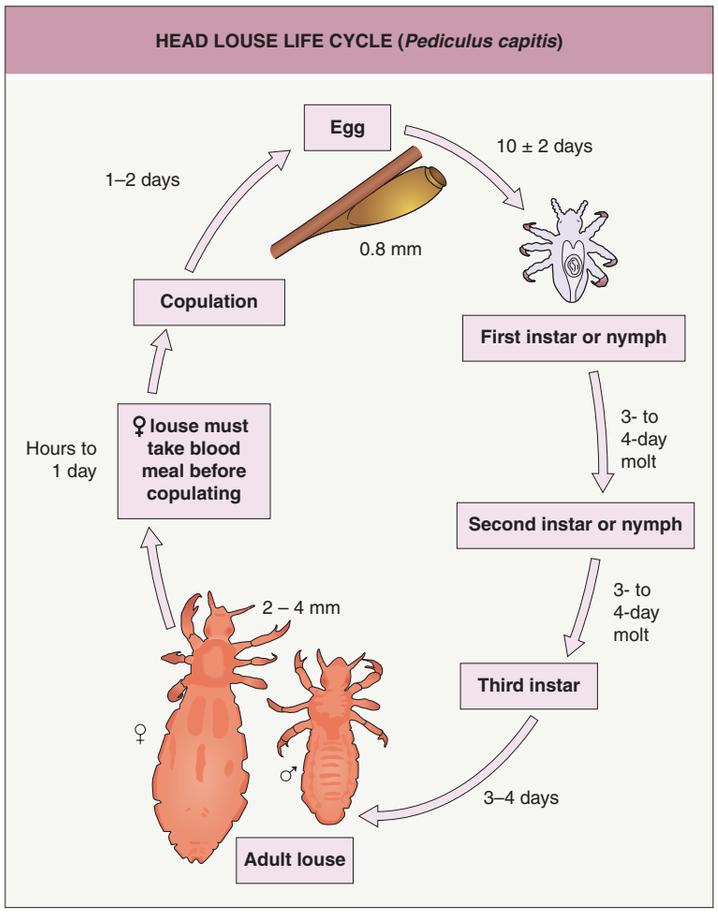

Fig. 84.8 Head louse life cycle (*Pediculus capitis*).

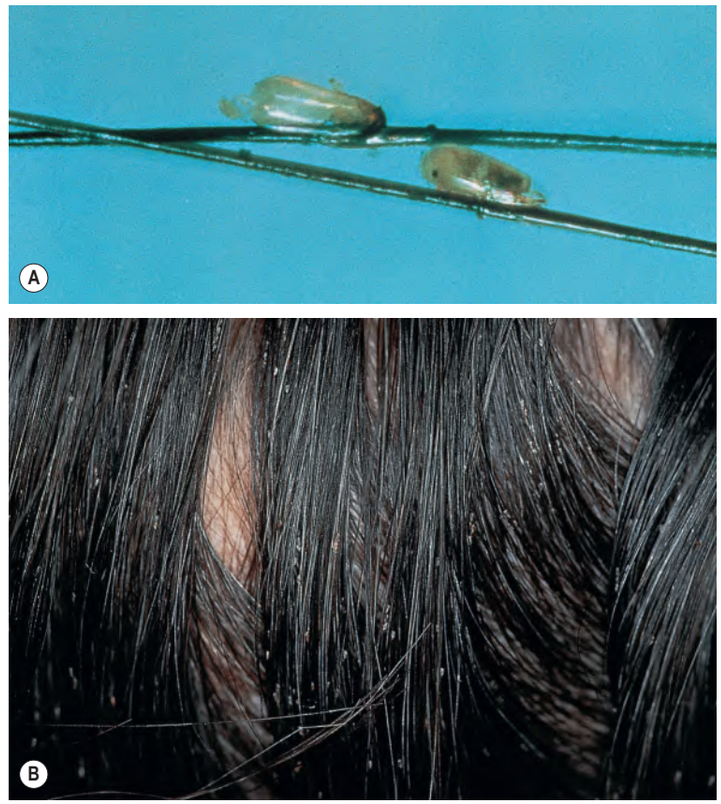

Fig. 84.9 Head lice. A The head louse egg or nit is 0.8 mm in length. **B** Head lice nits on hair. *With permission from Taplin D, Meinking TL. Infestations. In: Schachner LA, Hansen RC (eds). Pediatric Dermatology, 4th edn. Edinburgh: Mosby, 2011:1141–80.*

oval egg capsules (nits) measure 0.8 mm in length and are usually laid close to the scalp for warmth; in general, eggs located within 1 cm of the scalp are unhatched. In warm climates, however, viable nits may be found 15 cm or more from the scalp, especially in the area above the nape of the neck. The nits are cemented to individual hairs by a proteinaceous matrix that closely resembles the amino acid constituents of the human hair shaft itself[25,26]. Head lice rarely live for more than 36 hours away from the host without a blood meal; however, given an appropriate temperature (82–90°F/28–32°C) and level of humidity (70%–90%), nits can survive and hatch after 10 days away from the host. Transmission occurs via direct head-to-head contact or by fomites such as combs, brushes, blow-dryers, hair accessories, bedding, helmets, and other headgear[27].

Clinical Features

Skin findings of head lice infestation are limited to the scalp, behind the ears, and the nape of the neck. The classic symptom of intense pruritus varies among patients. It may take 2–6 weeks following an initial infestation before pruritus is evident, reflecting a delayed immunologic response to components of the lice saliva or excreta. In repeat infestations, pruritus develops within the first 24–48 hours. However, some individuals are asymptomatic "carriers". Although excoriations, erythema, pyoderma, and scaliness of the scalp and posterior neck are common findings, definitive diagnosis is made by the identification of nits and/or adult lice on the scalp hair. Viable eggs are usually tan to brown in color, whereas hatched eggs are clear to white (Fig. 84.9).

Patients occasionally present with a low-grade fever and lymphadenopathy due to a secondary bacterial infection. Head lice can carry *S. aureus* and *Str. pyogenes* on their surfaces and are a common cause of pyoderma of the scalp[1]. There is increasing evidence that head lice may harbor other pathogens such as *Bartonella recurrentis*, *B. quintana*, *Coxiella burnetii*, and *Acinetobacter* spp.; however, it is unclear whether this is associated with disease transmission[28,29].

Pathology

The epidermis and dermis may display nonspecific inflammation.

Differential Diagnosis

Although several dermatoses, such as seborrheic dermatitis and psoriasis, can cause pruritus of the scalp, the finding of nits or adult lice is diagnostic. Nits are more firmly adherent to the hair shaft than dandruff, dried hair products (e.g. sprays, gels) or hair casts, and they must be differentiated from other causes of hair shaft nodules such as piedra (white or black) and trichorrhexis nodosa (see Fig. 77.1).

Treatment

The choice of treatment is based on the efficacy and potential toxicity of different agents, insecticide resistance patterns in the geographic area, and ease of access to prescription remedies[30]. Pediculicides remain the mainstay of therapy (Table 84.2). With all topical preparations (regardless of package instructions), two applications, 1 week apart, are advisable in order to: (1) kill any nits that survived treatment; (2) better defend against the growing resistance to many pediculicides; and (3) reduce the risk of reinfestation by means of fomites. Conditioner should not be applied prior to topical medications, and the hair should not be rewashed for 1–2 days[30].

Unsubstantiated claims of successful treatment with alternative, non-pesticidal products, including petroleum jelly, hair pomade, olive oil, mayonnaise, vegetable oil and mineral oil, persist. Such products may slow the movements of adult lice and allow them to be more easily combed out of the scalp, but these substances are not lethal to lice. Several essential oils (e.g. combinations of tea tree, lavender, and eucalyptus oils) have been reported to be effective as lice therapy,[30,31] and they have been incorporated into various products that are typically found in health food stores. However, additional clinical studies are needed to confirm their safety and efficacy. Oral trimethoprim–sulfamethoxazole may potentially improve the efficacy of topical agents, but its routine use is not recommended[32].

Many school authorities enforce a "no-nit" policy and do not allow children to return to school if they have nits, regardless of whether they

Downloaded for Anonymous User (n/a) at Egyptian Knowledge Bank from ClinicalKey.com by Elsevier on March 10, 2024. For personal use only. No other uses without permission. Copyright ©2024. Elsevier Inc. All rights reserved.

TREATMENTS FOR HEAD LICE				
Treatment	**Group**	**Administration on days 1 and 8**	**Concerns**	**Efficacy & resistance**
Over-the-counter products				
Ivermectin lotion (0.5%)‡	Avermectin	Topical application for 10 minutes to dry hair	Potential skin and eye irritation	Good; single report of resistance to date
Dimethicone liquid gel, lotion, or spray (4%–100%)	Silicone oil	Topical application for 10–15 minutes or overnight	None	Good (varies with different formulations)
Pyrethrins (0.33%) synergized with piperonyl butoxide (4%), various formulations	Natural botanicals	Topical application for 10 minutes to dry hair	Allergic reactions in individuals with sensitivity to chrysanthemums, ragweed and related plants	Poor–fair; resistance common
Permethrin cream rinse or lotion (1%)	Synthetic pyrethroid	Topical application for 10 minutes to clean, dry hair	None	Poor–fair; resistance common
Prescription products (order based upon efficacy, but those ranked as Good are often used as first-line therapies)				
Malathion lotion or gel (0.5%)†	Organophosphate cholinesterase inhibitor	Topical application for 8–12 hours to dry hair (Ovide® and gel products with isopropyl alcohol base are effective at 20 minutes)	Flammable isopropyl alcohol base; burning or stinging at sites of eroded skin	Excellent (in US); resistance noted in Europe and Australia, but to date not in US
Oral ivermectin (available as 3 mg tablets)	Avermectin	Oral dose of 200–400 mcg/kg	Potential risk of CNS toxicity; not recommended for breastfeeding mothers or pregnant women (category C); recent studies suggest safety in children ≥1–2 months of age weighing <33 pounds (15 kg), but use is not well-established in this group	Excellent; single report of resistance to date
Spinosad suspension (0.9%)‡	Bacterial fermentation product	Topical application for 10 minutes to dry hair	Potential skin and eye irritation	Good; no resistance noted to date
Abametapir lotion (0.74%)‡	Metalloproteinase inhibitor	Topical application for 10 minutes to dry hair	Potential skin irritation	Good; no resistance noted to date
Benzyl alcohol lotion (5%)‡	Alcohol	Topical application for 10 minutes to dry hair	Potential skin irritation	Good; no resistance noted to date
Permethrin cream (5%)*	Synthetic pyrethroid	Topical overnight application to clean, dry hair	Allergic contact dermatitis in individuals with sensitivity to formaldehyde	Poor–fair; resistance common
Lindane shampoo (1%)	Organochlorine	Topical application for 4 minutes to clean, dry hair, then add water to lather and rinse	Potential CNS toxicity; not recommended for infants, children, breastfeeding mothers or pregnant women (category C)	Poor; resistance common
Carbaryl shampoo (0.5%)	Carbamate cholinesterase inhibitor	Topical application for 8–12 hours	Possible carcinogen	Poor–fair; resistance common (not approved in the US)

*Approved for individuals ≥2 months of age; considered safe during pregnancy.
†Approved for individuals ≥6 years of age; considered safe during pregnancy.
‡Approved for individuals ≥6 months of age; spinosad cream rinse, abametapir lotion, and benzyl alcohol lotion are considered safe during pregnancy.

Table 84.2 Treatments for head lice. In general, treatments should be given on two separate occasions, 1 week apart. However, the FDA-approved regimen for treatment of head lice with 0.5% ivermectin solution and abametapir 0.74% lotion is a single application. Airallé® is an FDA-cleared medical device that uses hot air to treat head lice via dehydration of their eggs and, to a lesser degree, hatched lice. Isopropyl myristate 50% in cyclomethicone solution (Resultz®) was FDA-approved as an over-the-counter treatment for head lice in 2017; it is available in Canada and Europe but has not yet been marketed in the US. Benzyl benzoate 10%–25% lotion or emulsion (over-the counter; not directly sold in US pharmacies) may be used for head lice, although there are few investigational studies; it is applied to the hair for 12–24 hours on days 1 and 8.

are viable or not. As a result, the tedious task of physically removing all nits via combs with closely spaced metal teeth is required. Currently there are no products that easily aid in nit removal[33]. Flexibility and understanding by school boards would be more welcomed than a straight adherence to a "no-nit" policy.

Pyrethrins

In the US, pyrethrins, 1% permethrin, and 0.5% ivermectin are FDA-approved, OTC topical pediculicides. Pyrethrin insecticides are derived from a natural extract of flower heads of *Chrysanthemum cinerariaefolium*. Patients allergic to chrysanthemums, ragweed, or related plants have experienced wheezing and dyspnea with use of the crude extract. Pyrethrins are presently formulated into lotions, shampoos, foam mousse, and cream rinses. The addition of piperonyl butoxide slows the biotransformation of pyrethrins by partially inhibiting the insects' cytochrome P450 enzymes, thereby initially improving effectiveness. Pyrethrin products are applied to the head for 10 minutes and then rinsed off. Due to growing resistance to this insecticide, treatment failures are now commonplace[1].

Permethrin

Permethrin is the only synthetic pyrethroid that is used worldwide for head lice. The OTC 1% permethrin cream rinses and lotions are applied for 10 minutes; however, an 8–12-hour application of the 5% cream used for scabies is an alternative therapy. Unfortunately, resistance to even the higher-concentration products has developed in head lice and other insects. Point mutations in the gene encoding the α-subunit of the insects' voltage-sensitive sodium channels commonly lead to a reduction

Downloaded for Anonymous User (n/a) at Egyptian Knowledge Bank from ClinicalKey.com by Elsevier on March 10, 2024. For personal use only. No other uses without permission. Copyright ©2024. Elsevier Inc. All rights reserved.

in the binding affinity of permethrin and other pyrethroids. However, some studies have found >85%–90% success rates for treatment with permethrin in children whose lice had these mutations, suggesting that other factors play a role in pyrethroid resistance[34].

Malathion

The prescription organophosphate malathion is a cholinesterase inhibitor. Although the recommended application time for topical malathion is 8 to 12 hours, with repeated treatment in 7 days if live lice are present, high efficacy has also been reported when the duration of application is reduced to 20 minutes[35]. The existing US product (Ovide® lotion) contains 78% isopropyl alcohol, which enhances its effectiveness but raises the issue of flammability. Some resistance to malathion products has been reported, especially in Europe and Australia[36].

Ivermectin

A 0.5% *topical* ivermectin preparation (Sklice® lotion) was FDA-approved in 2012 for the treatment of head lice in patients ≥6 months of age and is now available OTC. Topical ivermectin has been shown to kill permethrin-resistant head lice,[37] and the viability of lice hatched from treated eggs is severely compromised[38]. In two randomized controlled studies (total n=765), 74% of patients treated with a single 10-minute application of 0.5% ivermectin lotion to dry hair were lice-free after 15 days, compared to 18% of those who received a vehicle control (p<0.001)[39].

Oral ivermectin represents another therapeutic option for resistant head lice infestations. In a large multicenter clinical trial, 95% of patients with head lice that previously failed topical therapy (pyrethrin or malathion) who received 400 mcg/kg of ivermectin on days 1 and 8 were lice-free on day 15, compared to 85% of those treated with two applications of topical malathion[40]. In several other controlled studies, >90% of children treated with 200 mcg/kg of ivermectin on days 1 and 8 were lice-free at 2-week follow-up[41]. Because lice are only exposed to the drug while feeding, oral ivermectin has no ovicidal activity and (unlike topical ivermectin) two treatments are required. Of note, clinical ivermectin resistance associated with a mutation in the ivermectin target site was documented in head lice from two children from rural Senegal following a second oral ivermectin treatment[42].

Dimethicone

Dimethicone is a silicone oil that is used as an emollient in skin care products. Dimethicone-containing products may suffocate lice or block their ability to excrete water and result in death due to osmotic stress[43]. In several randomized controlled studies, 10-minute to overnight application of 4%–100% dimethicone liquid gel, lotion, or spray (e.g. LiceMD®, Hedrin®, NYDA®) on day 1 ± day 8 resulted in 70%–97% of patients being lice-free on day 14, representing significantly higher efficacy than treatment with 1% permethrin cream rinse or 0.5% malathion liquid in some reports[44,45].

Spinosad

In 2011, 0.9% spinosad topical suspension (Natroba™) was approved by the FDA as a therapy for head lice, and it is currently indicated for children ≥6 months of age. Spinosad is a fermentation product of the bacterium *Saccharopolyspora spinosa* that induces muscle spasms and paralysis in lice when applied topically. A clinical trial (n=1038) showed that 0.9% spinosad suspension left on for 10 minutes without nit combing on day 1 ± day 7 had superior efficacy to 1% permethrin cream with nit combing (~86% vs ~44%; p<0.001), and spinosad therapy led to no significant adverse effects[46].

Abametapir

In 2020, 0.74% abametapir lotion (Xeglyze™) was FDA-approved for the treatment of head lice in children ≥6 months of age. This metalloproteinase inhibitor targets metalloproteinases critical to the development of lice and their eggs. In two clinical trials (n=704), 86% of patients treated with a single 10-minute application of 0.74% abametapir lotion to dry hair were lice-free through day 14, compared to 63% of those treated with the vehicle (p<0.001)[47].

Benzyl alcohol

In 2009, the FDA approved 5% benzyl alcohol lotion (Ulesfia®) as a prescription treatment for head lice in children ≥6 months of age; benzyl alcohol is thought to act via asphyxiation by preventing lice from closing their respiratory spiracles, which become blocked by the lotion; it is not ovicidal. In two randomized, double-blind, controlled clinical studies (total n=250), 75% of patients were lice-free 14 days after the last of two 10-minute applications of benzyl alcohol (administered 1 week apart), compared to 5%–25% of those treated with a vehicle control[48]. Ulesfia has been discontinued; however generic benzyl alcohol may be commercially available.

Lindane

Lindane, a chlorinated hydrocarbon, is available as a 1% prescription shampoo that is applied for 4 minutes. Because of possible CNS side effects, especially after prolonged applications beyond the recommended time interval, the FDA has issued a "black box" warning that lindane is reserved for patients who fail to respond to other approved lice therapies. However, resistance to lindane is commonly observed.

Carbaryl

Like malathion, carbaryl is a cholinesterase inhibitor. It is available in a 0.5% lotion and shampoo in the UK and other countries. This product is not presently available in the US. In comparison to malathion, carbaryl is potentially more toxic to patients, while being less lethal to lice.

CRAB LICE

Synonyms: ▪ *Pthirus pubis* or *Phthirus pubis* ▪ Pubic lice ▪ Pediculosis pubis ▪ "Crabs"

Key features

- More properly designated "crab lice" (rather than "pubic lice") because infestations may involve other hair-bearing sites such as the beard, eyelashes, axillae, and perianal region
- Transmitted by sexual or close contact and to a lesser extent via contaminated clothing, towels, and bedding

Introduction

Infestation with *Pthirus pubis*, the crab louse, causes discomfort, pruritus, and embarrassment and may coexist with other sexually transmitted infections.

History

The parasitic relationship between humans and crab lice dates back to prehistoric times.

Epidemiology

The incidence rate may be slightly higher in men, probably because they have a greater amount of coarse body hair. Infestations with crab lice can be found in all socioeconomic and ethnic groups, although those of Asian descent or with minimal pubic hair are rarely affected. The incidence of crab lice has decreased with current cultural practices of hair removal from the pubic region[49]. Infestation is most frequently observed in those 15 to 40 years of age, correlating with increased promiscuous sexual activity. The highest prevalence is in men who have sex with men. Although infestation is often considered a sexually transmitted disease, individuals who have had no sexual exposures are occasionally infested via fomite transmission from contaminated clothing, towels, or bedding[1].

Pathogenesis

Crab lice, *Pthirus pubis*, are approximately 1 mm in length and resemble tiny crabs, with a wider, shorter body than head lice (Fig. 84.10). Crab lice eggs, which are found attached to human hairs, are viable for up to 10 days; the adult crab louse can live for at least 36 hours away from the host. Crab lice have serrated edges on their first claw that enable them to ambulate on the entire body surface. Thus, infestation occurs not only in pubic hair, but also in hair of the scalp, eyebrows, eyelashes,

Downloaded for Anonymous User (n/a) at Egyptian Knowledge Bank from ClinicalKey.com by Elsevier on March 10, 2024. For personal use only. No other uses without permission. Copyright ©2024. Elsevier Inc. All rights reserved.

Fig. 84.10 Adult crab louse. Respiratory spiracles and circulatory system are easily seen (45×). *Courtesy Tony Burns, MD.*

moustache, beard, axillae, and perianal area. Indeed, 60% of patients with pubic lice are infested in at least two hair-bearing sites. When the pubic area is shaved or treated, surviving crab lice can travel to other hairy areas of the body, including the scalp.

Clinical Features

Crab lice infestations typically present with pruritus in the pubic region. Crab lice cling to the base of hairs (Fig. 84.11A) and can be brown to skin-colored or mimic hemorrhagic crusts. Other findings may include nits at the base of hair shafts, erythema around hair follicles, excoriations, evidence of a secondary bacterial infection, and lymphadenopathy. When the eyelashes are affected (Fig. 84.11B), feces that accumulate can resemble flecks of mascara. Macula caerulea are asymptomatic, slate-gray to bluish, irregularly shaped macules that measure 0.5–1 cm in diameter and favor the trunk and thighs. These lesions, which typically develop in chronic crab lice infestations, are thought to result from the breakdown of bilirubin to biliverdin by enzymes in louse saliva.

In individuals with crab lice, the possibility of additional sexually transmitted infections should be considered and the original source of the infestation sought in order to reduce the risk of recurrence.

Pathology

Crab lice cause nonspecific inflammatory changes in the epidermis and dermis. Because lice live on the surface of the skin, they are not evident histologically.

Differential Diagnosis

The identification of crab lice and/or their nits is diagnostic (see Fig. 84.10). Skin diseases associated with pruritus that may be considered in the differential diagnosis include other infestations (e.g. scabies) and arthropod bites. Nits on pubic or axillary hairs must be distinguished from white piedra and trichomycosis pubis or axillaris.

Treatment

Topical insecticides are the standard therapy for crab lice. Sexual partners should be treated simultaneously. Most commonly, permethrin (1% or 5%) and synergized pyrethrin products are utilized (Table 84.3). As with head lice, the topical insecticide should be applied on two occasions, 1 week apart, to ensure complete eradication of hatched eggs. Moreover, all hairy areas of the body must be inspected for the existence of lice and treated if there is a possibility of infestation. A single application of topical products to only pubic hair may limit success rates to as low as 55%[50].

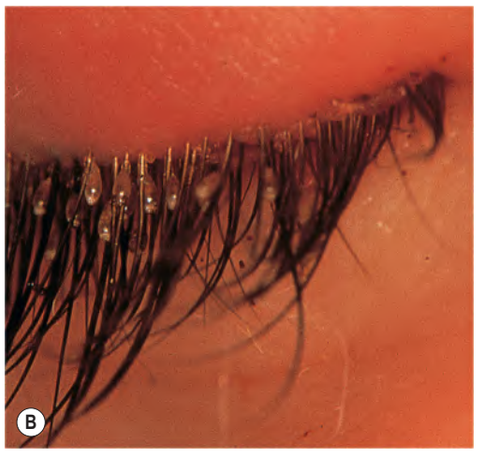

Fig. 84.11 Crab lice. A Both adult crab lice and nits are evident on pubic hairs. **B** Crab lice nits and feces on the eyelashes. *A, Courtesy Louis A. Fragola, Jr, MD; B, With permission from Taplin D, Meinking TL. Infestations. In: Schachner LA, Hansen RC (eds). Pediatric Dermatology, 4th edn. Edinburgh: Mosby, 2011:1141–80.*

Currently, the safest and most effective topical treatment is 5% permethrin cream applied generously overnight to all potentially infested hairy areas, and then repeated 1 week later[40]. Lindane has poor efficacy and higher toxicity, and the shampoo is not approved for extensive body application. Oral ivermectin on days 1 and 8 can be used for patients with perianal or eyelash involvement or when topical therapy is unsuccessful (see Table 84.3)[30,51].

BODY LICE

Synonyms: ▪ Pediculosis corporis ▪ Clothing lice

Key features

- An infestation of humans and their clothing, body lice most commonly affect the homeless, refugees, and victims of war and natural disasters
- Body lice do not live or lay eggs on people but in their clothing
- Infections transmitted by body lice include epidemic typhus, trench fever, and relapsing fever

Introduction

Body lice infestations are associated with overcrowding, poor hygiene, poverty, war, and natural disasters. These insects are the primary vectors for diseases caused by *Rickettsia*, *Borrelia* and *Bartonella* spp. (see Chs. 74 & 76). Body lice resemble head lice but are larger in size.

Downloaded for Anonymous User (n/a) at Egyptian Knowledge Bank from ClinicalKey.com by Elsevier on March 10, 2024. For personal use only. No other uses without permission. Copyright ©2024. Elsevier Inc. All rights reserved.

TREATMENTS FOR CRAB LICE			
Treatment	**Administration on days 1 and 8**	**Concerns**	**Efficacy**
Permethrin (1%) cream rinse or synergized pyrethrin shampoo*	Topical application for 10 minutes to clean, dry hair	None	Fair
Permethrin cream (5%)	Topical application for 8–12 hours	Allergic contact dermatitis in individuals with sensitivity to formaldehyde	Good
Lindane shampoo (1%)	Topical application for 4 minutes to dry hair, then add water to lather and rinse	Potential CNS toxicity; not recommended for infants, children, breastfeeding mothers or pregnant women (category C)	Poor
Ivermectin	0.5%–1% lotion/cream topically overnight	Potential skin and eye irritation	Not established
	Oral dose of 250 mcg/kg (available as 3 mg tablets)	Potential CNS toxicity; not recommended for breastfeeding mothers or pregnant women (category C)†	Excellent

*Over-the-counter products.
†Recent studies suggest safety for children ≥1–2 months of age weighing <33 pounds (15 kg), but use is not well-established in this group.

Table 84.3 Treatments for crab lice. All crab lice treatments should be given on two separate occasions, 1 week apart, i.e. days 1 and 8. Benzyl benzoate 10%–25% lotion or emulsion (over-the counter; not directly sold in US pharmacies) may be used for crab lice, although there are few investigational studies; it is applied three times over a 24-hour period without an intervening bath.

Epidemiology

Body lice are found worldwide. Increased prevalence rates of body lice are tied to poor hygiene, poverty, and homelessness. There are no racial, age, or sex restrictions.

Pathogenesis

Pediculosis corporis is caused by an infestation of humans and their clothing by *Pediculus humanus* var. *corporis*. In addition to exposure to conditions conducive to obtaining body lice, infestation requires an inability to wash and change clothes.

Several important human diseases are transmitted by the body louse. These include epidemic typhus (*Rickettsia prowazekii*) and relapsing fever (*Borrelia recurrentis*) as well as several diseases caused by *Bartonella quintana* – trench fever, bacillary angiomatosis, and endocarditis[30,52]. Whether this louse has a role in transmission of *Acinetobacter baumannii* or *Yersinia pestis* to humans remains to be determined[52]. Transmission of microorganisms from body lice to humans occurs not from louse bites, but rather from inoculation of louse feces into the skin via scratching or by inhalation of dry, powdery louse feces from infested bedding or clothing.

Clinical Features

P. humanus var. *corporis* measures between 2.5 and 4.0 mm in length. Unlike head and crab lice, the nits and lice are rarely found on the patients' skin, save for feeding, as they reside primarily on the clothing of their hosts. This infestation leads to severe pruritus. The back, neck, shoulders, and waist areas are commonly involved. Clinical findings include pinpoint red macules, small erythematous papules, crusts and excoriations, occasionally complicated by impetigo and lymphadenopathy. Blood and fecal pellets often stain clothing and bedding. On inspection, nits and adult lice are found along clothing seams that are in contact with the neck, axillae, and waistline (Fig. 84.12).

Fig. 84.12 Body lice eggs in the seams of clothing.

Pathology

The epidermis has minimal spongiosis with nonspecific infiltrates of eosinophils and neutrophils in the dermis.

Differential Diagnosis

Other causes of widespread pruritus and excoriations that may be considered in the differential diagnosis of body lice include systemic diseases (e.g. hepatic or renal impairment), drug reactions, atopic dermatitis, contact dermatitis (irritant or allergic), and other infestations (e.g. scabies).

Treatment

Preferably, the clothing and bedding of infested individuals should be discarded in tightly sealed, plastic biohazard bags and incinerated. Only if the latter is not possible should disinfection be attempted. This involves fumigating the clothing or laundering it using hot water (temperature of ≥130°F/55°C), followed by machine drying with high heat. Hot ironing of the seams of upholstered furniture can also be performed, and exposure to untreated infested items should be strictly avoided for 2 weeks. Topical insecticide regimens similar to those used for scabies can eradicate concurrent scabies or crab lice infestations as well as kill any body lice adherent to hairs.

Mass delousing in crowded, large populations due to natural disaster, war, or famine is accomplished by dusting powders. These powders may contain DDT, malathion, dieldrin, lindane, or permethrin.

TUNGIASIS

Synonyms: ▪ *Tunga penetrans*: chigoe flea, jigger flea, burrowing flea, sand flea ▪ Pique ▪ Nigua ▪ Pio and bicho de pie

Key features

- This infestation is caused by the burrowing flea, *Tunga penetrans*
- It is endemic in the Caribbean islands and parts of Central and South America, Africa, Pakistan, and India
- The female flea burrows into the skin and then enlarges to create a nodule with a central punctum through which eggs are ejected

Introduction

The burrowing flea, *Tunga penetrans*, is the causative agent of tungiasis. A female flea burrows into the upper dermis and enlarges to approximately 1 cm in diameter, creating a nodule with a central punctum through which eggs (fertilized or unfertilized) are eventually discharged.

Downloaded for Anonymous User (n/a) at Egyptian Knowledge Bank from ClinicalKey.com by Elsevier on March 10, 2024. For personal use only. No other uses without permission. Copyright ©2024. Elsevier Inc. All rights reserved.

Fig. 84.13 Tungiasis in a child.

History

Tungiasis was first reported in crew members on Christopher Columbus' original trip to the New World in 1492.

Epidemiology

Tungiasis can occur in anyone exposed to the flea, regardless of sex, race, or age. Areas of high incidence include the Caribbean islands, parts of Central and South America, and sub-Saharan Africa. In endemic areas, risk factors include walking barefoot, wearing open-toed shoes, and living in homes with dirt or unclean floors[30].

Pathogenesis

Tunga penetrans is a wingless flea that is 1 mm in size and usually lives in warm, dry soil. Both sexes of this flea require an occasional blood meal from a warm-blooded animal for maturation[53]. Due to the fleas' limited jumping ability, the most common location for bites is the foot. Female fleas, rather than simply obtaining a blood meal, burrow headfirst into mammalian skin. They subsequently undergo marked abdominal hypertrophy, growing to 1 cm in diameter. The flea protrudes its rear cone through a central punctum that is always maintained; whether or not fertilization occurs via mating of the embedded female flea with a free-roaming male flea, over a hundred eggs are discharged within 3 weeks[53]. After expelling the eggs, the female dies and its remains are eventually sloughed from the skin.

Clinical Features

Bites of immature fleas cause no symptoms; however, burrowing of the female flea into the skin can cause significant clinical morbidity. The burrowing is initially asymptomatic, but varying degrees of pain or pruritus usually develop. The first sign of disease is a small black dot, which evolves into a pearl-like whitish papule and then a larger nodule that is said to resemble a watch glass, with a clearly demarcated white halo surrounding the black central punctum. A peripheral zone of erythema is frequently evident. When the flea dies, a black crust covers the involuting lesion. The Fortaleza classification scheme divides tungiasis into stages based upon symptoms, lesion size and the clinical appearance[53].

The most common site of disease is the periungual area of the toes, followed by the soles and toe webs (Fig. 84.13). Ulceration, secondary infection, and lymphangitis can occur; less frequent complications include tetanus, gangrene, and amputation of a digit[53]. Over half of periungual infections lead to deformation or loss of the nail, and heavy infestations produce substantial morbidity in resource-poor communities within endemic areas[54,55].

Pathology

A nonspecific inflammatory infiltrate surrounds the flea within the dermis.

Differential Diagnosis

The differential diagnosis may include myiasis, tick bite reactions, cercarial dermatitis, pyoderma, plantar warts, verruga peruana, and squamous cell carcinoma.

Treatment

Spontaneous recovery does occur; however, most clinicians and patients prefer to treat the infestation by removal of the female flea. In an early infestation, a sterile needle can be used to pry the insect from the skin. Covering the punctum with dimethicone, liquid paraffin, or a mixture of neem and coconut oils may prevent flea growth and expedite removal[54–56]. If treatment is delayed, curettage, electrodesiccation, or surgical excision may be required. Careful cleaning of the cystic cavity speeds clinical resolution, and antibiotic therapy may be needed for secondary infections. Tetanus prophylaxis should be strongly considered. Topical application of ivermectin, metrifonate, or thiabendazole may lead to more rapid demise of embedded fleas, but this has limited clinical benefit[54,55]. In a randomized controlled study, oral ivermectin was not found to have significant efficacy compared to placebo.

Preventative measures include wearing closed shoes or boots and avoiding ground contact in endemic areas. A plant-based insect repellent containing coconut and jojoba oils has also been shown to prevent sand flea infestation[55].

CUTANEOUS MYIASIS

Synonym: ■ Names for the various flies associated with this entity include human botflies, screwworms, blowflies, fleshflies, and tumbu flies

Key features

- Infestation of the skin by fly larvae (maggots)
- The larvae inhabit cutaneous wounds (wound myiasis) or burrow into the dermis causing boil-like lesions (furuncular myiasis)
- Although they usually cause minimal morbidity, larvae can cause problems when they involve the nasal cavity and sinuses

Introduction

Cutaneous myiasis is an infestation of the skin by developing larvae (maggots) of a variety of fly species within the arthropod order Diptera. The two main clinical types are wound and furuncular myiasis.

History

Maggots were central to Francesco Redi's experiment rejecting the theory of spontaneous generation. Wound debridement by maggots has been used for centuries, including during the American Civil War and by Napoleon's troops.

Epidemiology

Myiasis is a worldwide infestation with seasonal variation whose prevalence is related to latitude and the life cycle of the various species of flies. Its incidence is higher in the tropics and subtropics of Africa and the Americas. The flies responsible prefer a warm and humid environment, thus they are restricted to the summer months in temperate zones, while living year-round in the tropics.

Pathogenesis

Myiasis is the infestation of living humans (or other vertebrates) with dipterous larvae that feed on the host's tissues, liquid body substances, or ingested food. Myiasis can be caused by several species of arthropods

Downloaded for Anonymous User (n/a) at Egyptian Knowledge Bank from ClinicalKey.com by Elsevier on March 10, 2024. For personal use only. No other uses without permission. Copyright ©2024. Elsevier Inc. All rights reserved.

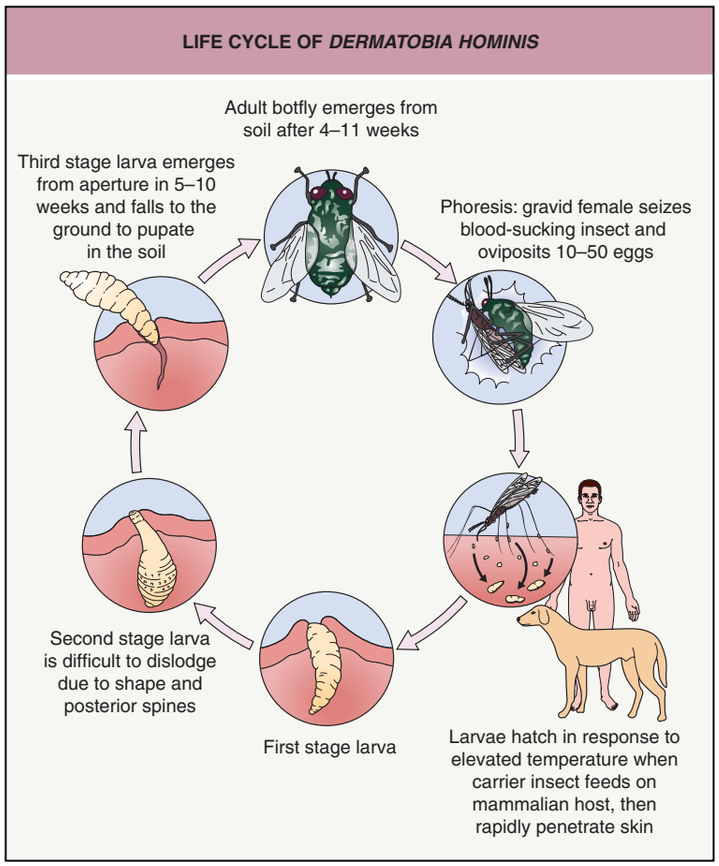

Fig. 84.14 Life cycle of *Dermatobia hominis* in cutaneous myiasis.

within the order Diptera, the two-winged true fly. The causative flies can be classified by: (1) taxonomic family; and (2) differences in pathogenic behavior of the fly species.

Worldwide, the most common flies that cause human infestation are *Dermatobia hominis* (human botfly) and *Cordylobia anthropophaga* (tumbu fly). The routes of transmission of fly larvae to human hosts differ among the fly species. For example, *D. hominis* lays its eggs on mosquitoes, which in turn deposit them on a warm-blooded mammal (Fig. 84.14). *C. anthropophaga* deposits its eggs on moist clothing and soiled blankets and in sand. The larva can live 15 days without feeding, but once it makes contact with a host, it penetrates the skin, which initiates further maturation. In endemic areas, people often iron their clothes after hanging them out to dry to kill the fly eggs. In wound myiasis, an open wound or orifice attracts flies to deposit their eggs. Any body area can be infested, and the most serious sequelae occur when the nasal cavity, sinuses, or scalp are involved. The incubation period for larvae to mature into adulthood depends on the fly and can range from 1 to 12 weeks.

Clinical Features

Furuncular cutaneous myiasis, which is caused by the human botfly and tumbu fly, causes boil-like lesions. Whereas myiasis from the tumbu fly typically occurs on the trunk, thighs and buttocks, botfly lesions are usually on exposed areas of the body, including the scalp, face, forearms and legs. A pruritic papule develops within 24 hours of penetration, enlarging to a 1–3 cm nodule with a 2–3 mm central punctum (Fig. 84.15A–C). These lesions can be painful or tender and may become crusted and purulent; there may be a sensation of movement.

In *wound* myiasis, the larvae are deposited in a suppurating wound or on decomposing flesh. *Cochliomyia hominivorax*, a screwworm, is the most common cause of this form of myiasis in the Americas, while *Chrysomya bezziana* is typically seen in Africa, Australia, and Asia. The diagnosis is obvious when larvae are visible on the surface of the wound (Fig. 84.15D) and more difficult when they have burrowed beneath the surface.

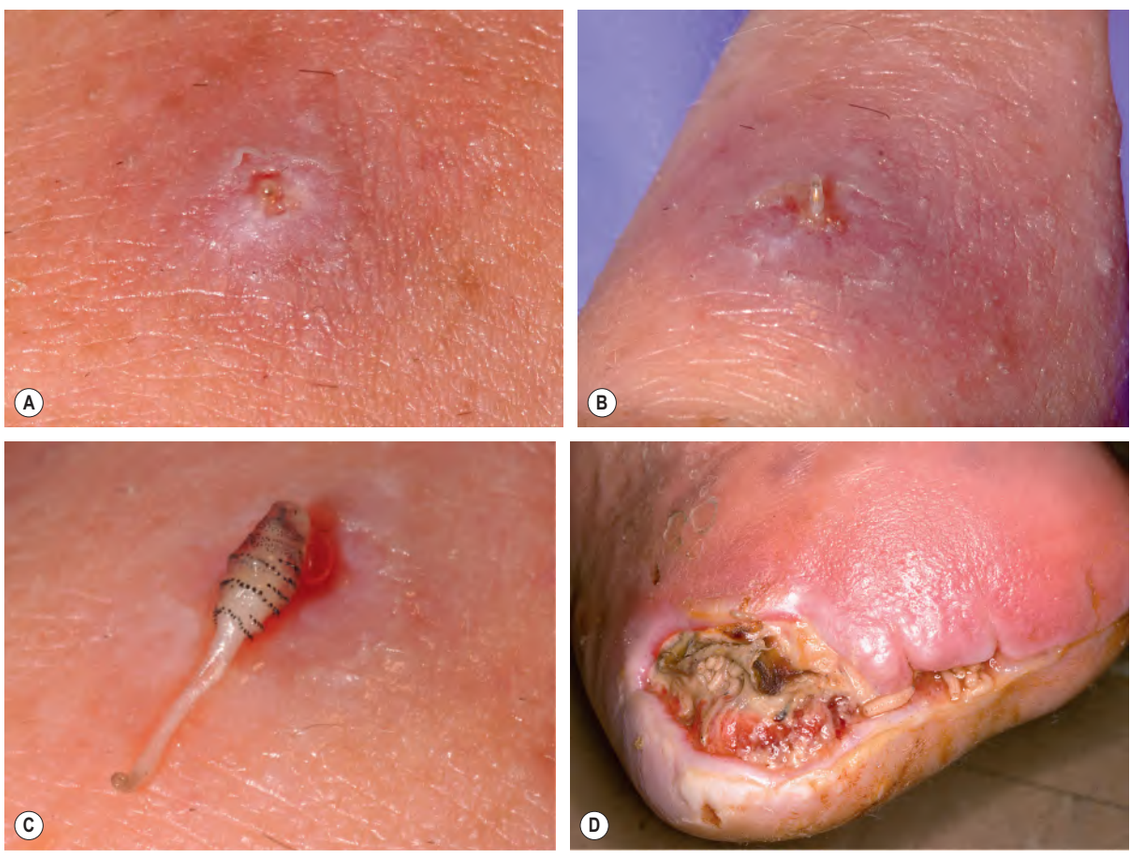

Fig. 84.15 Cutaneous myiasis. A–C Furuncular myiasis on the forearm presenting as a papulonodule with a central punctum (**A**) through which the larva's posterior end, which contains respiratory spiracles, may protrude (**B**). Note the characteristic appearance of the extracted botfly larva, with parallel rows of dark spines and hooks (**C**). **D** Wound myiasis in an amputation stump. *A–C, Courtesy Edward W. Cowen, MD; D, Courtesy Louis A. Fragola, Jr, MD.*

Downloaded for Anonymous User (n/a) at Egyptian Knowledge Bank from ClinicalKey.com by Elsevier on March 10, 2024. For personal use only. No other uses without permission. Copyright ©2024. Elsevier Inc. All rights reserved.

Creeping (or migratory) cutaneous myiasis may be caused by *Hypoderma bovis* if there is exposure to infested cattle, or by *Gasterophilus intestinalis* in those who work with horses. This form of myiasis resembles cutaneous larva migrans, but the fly larvae migrate more slowly, persist for longer (often months), and are larger than helminth larvae.

Myiasis is a self-limiting infestation with minimal morbidity in the vast majority of cases. The major reasons for treatment are reduction of pain, cosmesis, and psychological relief. However, larvae such as *C. hominivorax* can infest around orifices of the head and may burrow into brain tissue.

Pathology

Histologically, an inflammatory response occurs in stages in which lymphocytes, giant cells, neutrophils, eosinophils, mast cells, and plasma cells participate. The larvae can be seen in cross-section.

Differential Diagnosis

Furuncular cutaneous myiasis should be differentiated from a ruptured epidermoid cyst, an abscess, furunculosis, a foreign body reaction, onchocerciasis, tungiasis, an exaggerated arthropod bite reaction, and lymphadenopathy.

Treatment

The larva in furuncular cutaneous myiasis should not be forcibly removed through the central punctum because its tapered shape with rows of spines and hooks prevents simple extrusion (see Fig. 84.15C). Surgical debridement under local anesthesia is curative, although a foreign body reaction can occur if parts of the larva remain[56]. Occlusion/suffocation approaches involve placement of petroleum jelly, liquid paraffin, beeswax, nail polish, heavy oil, lard, or strips of bacon over the central punctum[56,57]. Such blockage forces the aerobic larva to surface for air over the course of several hours – at which time, forceps aid in their capture. Alternatively, ethyl chloride sprays, liquid nitrogen, chloroform in vegetable oil, or insecticides have been used alone or in combination. In addition, the larva can be forced to the surface by injecting lidocaine into the base of the tissue cavity or by using a suction-based venom extractor[57,58]. After removal of larvae, antiseptic dressings are indicated, as are antibiotics if secondary infection is present.

Wound myiasis requires debridement with irrigation to eliminate the larvae from the wound, or surgical removal. If burrowing has occurred, the method of extraction is identical to that for furuncular cutaneous myiasis.

An alternative treatment for all types of myiasis is oral ivermectin, which has proven especially helpful with oral and orbital involvement[56]. Surgical removal is not required unless requested by the patient, as the larvae are naturally sloughed within 2 weeks. Myiasis can be a portal of entry for *Clostridium tetani*, and vaccination of affected individuals should be considered.

Preventative Measures

In endemic areas, it is important to avoid activities that increase the risk of myiasis, such as wearing damp clothing or resting in sandy areas. The use of insect repellents (including on the scalp) can be useful in preventing mosquitoes that are harboring the larvae of the human botfly from depositing their living cargo.

Additional figures and tables on Diagnostic criteria for scabies, and Inpatient management of classic scabies and crusted scabies, available in our eBook (see inside front cover for access code).